

Chapter 17

Endocrine System

17.1. Introduction

The organs of the endocrine system are multicellular glands of epithelial origin. The parenchyma of endocrine organs is composed almost exclusively of epithelial cells. The endocrine glands will typically develop from an evagination of the epithelium which has lost its attachment to the free surface from which it arose. As a result these glands will be ductless. Instead of releasing their products into ducts, the product is released into the interstitial space. The endocrine gland will generally be embedded in a connective tissue so it is into the interstitial space of the connective tissue that the product is released.

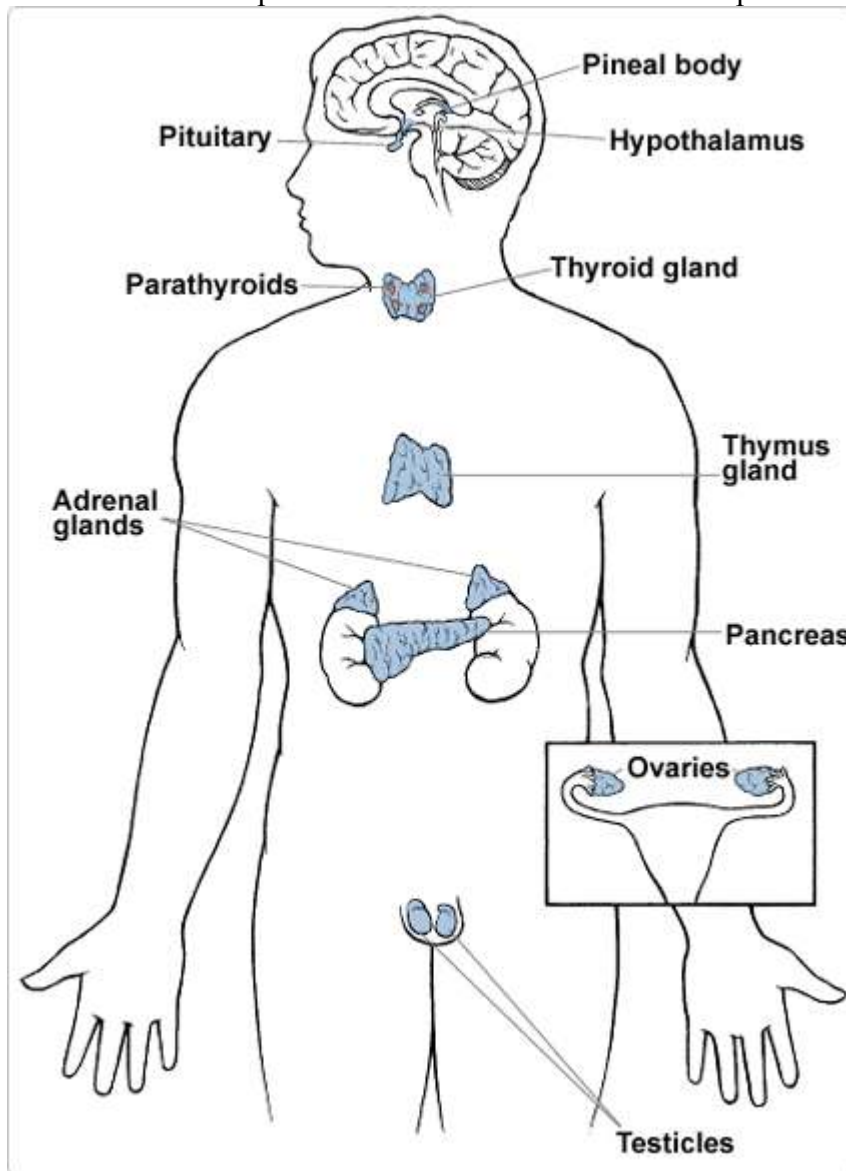


Fig.17.1. The Endocrine System

The connective tissue will be very well vascularized. Due to their need to distribute their products by the blood, the relationship between the endocrine gland and its microvasculature is intimate. Most often the microvascular component of the endocrine organ is composed of fenestrated capillaries. The structural organization of endocrine glands will vary. Most are free standing distinct entities. Some, however, are in close association with exocrine glands. Ex: the Leydig cells of the testis, the islets of Langerhans amid the exocrine component of the pancreas. Endocrine glands are simpler in their organization than are exocrine glands. They lack ducts. The parenchyma consists of cords, cluster, or follicles of cells. In the case of cord arrangement, the cords can be arranged into columns. Endocrine glands will have a closely integrated microvascular component. The endocrine product is the hormone. Hormones will elicit a response on the target organ/cells. The hormone is recognized by the target cell either by receptor proteins located on the cell membrane or by specialized proteins in the nucleoplasm. The type of hormone produced will vary with the organ and even the type of cell in the organ. The parenchyma cells of the endocrine organ will demonstrate the typical secretory adaptations: The cells will have numerous Golgi, mitochondria, and extensive endoplasmic reticuli. The hormones will often be contained in secretory vesicles located in the apical portion of the cytoplasm. Hormones are divided into two large classes based on their chemistry.

[1] **Steroid Hormones** - synthesized from steroid compounds. They will be recognized by proteins in the nucleoplasm.

[2] **Nonsteroid Hormones** - synthesized from amino acids. They can not enter the cell and so will bind to specific receptor proteins on the cell membrane which will elicit changes within the cell. There are a variety of these nonsteroid hormones: amine hormones, peptide hormones, protein hormones, and glycoprotein hormones. All of the other chemical messengers of the body, such as neurotransmitters and prostaglandins, are not technically considered to be hormones because their chemistry does not fit into these two classes.

17.2. The Pituitary Gland or Hypophysis

The pituitary is a compound gland of both neurosecretory and endocrine roles. It is located in the sella turcica of the sphenoid bone. The pituitary is attached to the Hypothalamus by a stalk-like structure called the Infundibulum. The pituitary gland is composed of two lobes which are distinctly dissimilar in terms of structure, function, and origin.

17.2.1. Anterior Pituitary/Adenohypophysis

This is the true endocrine portion of the pituitary. It develops from the epithelium of Rathke's Pouch. This epithelium is of ectodermal origin. Rathke's pouch is a structure of the nasopharynx/roof of the mouth in primitive vertebrates (i.e.; lampreys and hagfish). A group of epithelial cells will evaginate from it towards the brain. This cluster of cells will lose its attachment to Rathke's pouch and join with the other lobe of the pituitary. The anterior pituitary is composed of three regions: Pars Distalis, Pars Tuberalis, and Pars Intermedia. The pars intermedia is a relatively avascular zone which is considered to separate the two lobes (although, due to its endocrine nature, it is considered to be a part of the adenohypophysis). The anterior pituitary produces a wide range of hormones. The

release of these hormones is under the control of the hypothalamus. The hypothalamus is highly vascularized and so can monitor the body's internal environment. The hypothalamus will produce a variety of Regulating Factors in response to the body's condition. These regulating factors are chemical messengers that will stimulate or prevent the release of the anterior pituitary hormones. A pair of regulating factors is produced for almost every anterior pituitary hormone one factor to stimulate release and one to inhibit release. The regulatory factors are carried to the anterior pituitary by the blood vessels of the Hypophyseal-Hypothalamic Portal System.

a) The Pars Distalis of the Adenohypophysis

1) General Comments: The pars distalis comprises 75% of the glandular volume of the adenohypophysis. The pars distalis is enclosed in a fibrous connective tissue capsule. The epithelial cells of the parenchyma are arranged into clumps and cords. Separating these epithelial cells aggregates is some loose connective tissue containing sinusoids. The parenchyma contains three recognized epithelial cell types:

a) Chromophobes: Chromophobes are poor staining cells containing only a few granules. There is some evidence that this is not a distinct cell type but represents members of the other two cell types which have released their products. They are the least abundant cell type.

b) Acidophils/Alpha Chromaphils: Acidophils are much more numerous than are chromophobes. Acidophils stain well due to their numerous acidophilic granules. These granules give the cytoplasm a distinct granular appearance. Acidophils are attributed with the production of two hormones. The two hormones are: Human Growth Hormone (HGH) or Somatotropin which stimulates growth. Prolactin (PRL) which stimulates milk production. Due to the production of these two hormones, there are two types of acidophils recognized: Somatotropes produce HGH. And Mammotropes produce PRL.

c) Basophils/Beta Chromaphils: Basophils are larger cells than are acidophils and contain numerous basophilically staining granules. However, the granules of basophils are smaller and less numerous than are those of acidophils. Basophils produce an even greater variety of hormones with four products. The products are: Adrenocorticotropic Hormone (ACTH) stimulates the release of hormones by the adrenal cortex. The term for a hormone which controls the release of other hormones is Tropic. Thyroid Stimulating Hormone (TSH) stimulates the release of hormones by the thyroid gland. Leutinizing Hormone (LH) stimulates a variety of reproductive responses. Follicle Stimulating Hormone (FSH) stimulates gametogenesis. The different products are produced by different types of basophils. 1} Corticotropes produce ACTH. 2} Thryotropes produce TSH. 3} Gonadotropes secrete LH and FSH.

b) The Pars Tuberalis of the Adenohypophysis

The pars tuberalis is histologically quite similar to the pars distalis and has all three cell types.

c) The Pars Intermedia of the Adenohypophysis

The pars intermedia is rudimentary in humans compared to other vertebrates. It is an avascular zone between the anterior and posterior pituitary. The portion closest to the rest of the anterior pituitary is more like the anterior pituitary histologically. The epithelial component appears as a diffuse aggregate of basophils. These basophils are attributed with producing three hormones: Melanocyte Stimulating Hormone (MSH) which stimulates melanogenesis. Endorphins which are a class of pain-killing substances.

Lipoprotein which regulates lipid metabolism.

17.2.2. Posterior Pituitary/Neurohypophysis

This is the neurosecretory portion of the pituitary. It stores and releases neurosecretions from the hypothalamus. It develops from an evagination of the brain floor. It also is of ectodermal origin. The cells which migrated superiorly from Rathke's pouch will wrap around this evagination forming the pituitary gland. The posterior pituitary is also composed of three regions: Pars Nervosa, Infundibular Stalk, and the Median Eminence. The median eminence is a midline structure on the floor of the brain serving as the convergence of the nervous component. The infundibular stalk has both nervous and glandular elements.

a) The Pars Nervosa of the Neurohypophysis

The pars nervosa makes up the vast bulk of the neurohypophysis. The pars nervosa is composed primarily of a dense bundle of unmyelinated neuronal axons. These axons originate in the hypothalamus from cells termed Neurosecretory Cells. The axons pass, from the hypothalamus, through the infundibular stalk and median eminence to the pars nervosa. So these axons make up the bulk of the infundibulum and median eminence also. The cell bodies of the neurosecretory cells are found in two hypothalamic nuclei. They are the: Supraoptic Nucleus and Paraventricular Nucleus. Secretions from the neurosecretory cells travel down the axons into the pars nervosa where they accumulate.

The secretions accumulate at the axon terminals at the pars nervosa. These accumulated secretions are visible under the light microscope and are called Hering Bodies. These secretions are called the hormones of the posterior pituitary. There are two hormones of the posterior pituitary: Antidiuretic Hormone (ADH) which helps to regulate urine production. Oxytocin which stimulates the ejection of milk and may play a role in the orgasmic response. Each of these hormones is produced by a different hypothalamic nucleus. ADH is produced from the supraoptic nucleus. Oxytocin is produced by the paraventricular nucleus. These products will be picked up by fenestrated capillaries of the posterior pituitary. Among the neurosecretory axons of the pars nervosa are the Pituicytes. Pituicytes are neuroglia like cells that may support the neurosecretory axons.

b) The Median Eminence and Infundibulum of the Neurohypophysis

The bulk of these structures are filled by the axons of the neurosecretory cells traveling towards the pars nervosa.

17.2.3. The Blood Supply of the Hypophysis

There are two sets of arteries servicing the hypophysis.

- 1) The Inferior Hypophyseal Arteries supply most of the neurohypophysis.
- 2) The Superior Hypophyseal Arteries supplies the adenohypophysis (primarily pars distalis) and the median eminence.

These arteries will branch off of either the internal carotids of the circle of Willis (which encircles the hypothalamus). The superior hypophyseal arteries will branch into two microcirculatory beds in the pars distalis and median eminence. In the pars distalis the microcirculatory bed is composed of sinusoids which will pick up the products of the anterior pituitary for release into circulation. The two microcirculatory beds are connected by the Hypophyseal Portal Vein. The hypophyseal portal vein connects the microcirculatory component of the anterior pituitary to the capillary bed of the hypothalamus. This allows for control by the hypothalamus over the production of hormones by the anterior pituitary and forms the hypophyseal-hypothalamic portal

system. The anterior pituitary will be drained by the Inferior and Superior Hypophyseal veins which will empty into the internal jugular veins.

17.3. The Thyroid

The thyroid is typically a bilobed structure located in a connective tissue space above the manubrial notch, in the lower neck. It develops from an evagination of the epithelium from the inferior surface of the base of the tongue. Although it is typically bilobed, with the two lateral lobes, in some individuals there is a third lobe called the pyramidal lobe. The two lateral lobes are connected by the isthmus of the thyroid. The connective tissue capsule of the thyroid will extend into the gland. These inward extensions are called septa and divide the gland into poorly defined lobes and lobules. So the thyroid displays the typical lobulization of a gland. There are two classes of parenchyma cells in the thyroid: follicular cells and parafollicular cells.

17.3.1. Follicular/Principle Cells

The follicular cells are arranged into hollow spheres called Follicles. The follicle consists of a single layer of epithelial cells enclosing a central lumen. The follicle cells secrete their product into the lumen where it is stored as a colloidal mass called Thyroglobulin. When stimulated by TSH to release the products of the follicular cells the hormones are transported into the microcirculatory component outside of the follicle by pinocytosis. Surrounding each follicle is a basement membrane. Around the basement membrane is a sparse loose connective tissue rich in reticular fibers that forms a "barrier" between adjacent follicles. The fenestrated capillaries and nerves of the thyroid gland are found in this loose connective tissue. The follicular cells range from low cuboidal to tall columnar. Their products are collectively called the "thyroid hormones" and include thyroxine and triiodothyronine.

17.3.2. Parafollicular Cells

Parafollicular cells are found in small clusters. They are located between the follicular cells and the basement membrane of the follicle. They are much less numerous and smaller than are the follicular cells. Unlike follicular cells, the parafollicular cells are **not** in contact with the lumen of the follicle. They release their product directly into the fenestrated capillaries. Parafollicular cells have distinct cytoplasmic granules. These granules contain the endocrine product Thyrocalcitonin/Calcitonin. Thyrocalcitonin regulates blood-calcium levels by inhibiting osteoclastic activity.

17.4. The Parathyroids

The parathyroid glands are two pairs of small, pea-sized glands located on the posterior surface of the lateral lobes of the thyroid. They are distinguished from the thyroid by the presence of their own fibrous connective tissue capsule. This capsule will extend septa into the parathyroid dividing it into incomplete lobes. The vessels of the parathyroid will travel into the lobes along these septa. The parenchymal cells of the parathyroids are arranged into irregular anastomizing cords or groups supported by a reticular fiber framework. They will infrequently form follicles. Adipose will begin to accumulate with age among the parenchyma cells. There are two cell types making up the population of parenchyma cells in the parathyroids: principle cells and oxyphil cells.

17.4.1. Principle/Chief Cells

Principle cells are small, polyhedral epithelial cells. They are the more numerous of the two cell types. They will contain granules containing the endocrine product Parathyroid

Hormone (PTH). Parathormone regulates blood-calcium levels by stimulating osteoclastic activity. These cells will often be arranged in cords or clusters.

17.4.2. Oxyphil cells

Oxyphil cells are larger, less numerous, and strongly acidophilic cells. They do not appear until the onset of puberty and increase in number with age. Clusters of oxyphil cells will be found amid cords of principle cells. The function of oxyphil cells is still undetermined.

17.5. The Adrenal Glands

17.5.1. General Comments

The adrenal glands are paired organs located superior to the kidneys in the adipose capsule. Each adrenal gland is in actuality two endocrine glands contained in a common loose connective tissue capsule. These two glands are the Adrenal Cortex and the Adrenal Medulla. The adrenal cortex and adrenal medulla are of different origins and display different functions. The adrenal cortex is of mesodermal origin and develops from the mesothelium of the abdominopelvic cavity. It is a true endocrine structure and is rich in epithelial cells. The adrenal medulla is of ectodermal origin and develops from neural crest cells. In many ways it could be considered to be a sympathetic ganglion. PNS ganglia also arise from neural crest cells.

17.5.2. The Adrenal Cortex

The adrenal cortex is the outer portion of the adrenal gland. It is an epithelial structure.

The adrenal cortex is histologically and functionally divided into three regions:

a) Zona Glomerulosa - is the outermost region/layer of the adrenal cortex. It is a thin layer composed of spherical groups of epithelial cells called Glomerulosa Cells. These spherical groups resemble secretory acini (of exocrine glands) except that they lack the characteristic lumen (and associated duct). The glomerulosa cells are pyramidal to columnar in shape. The appearance of the glomerulosa cells is consistent for that of a secretory cell. Like other cells of the adrenal cortex, the cells of the zona glomerulosa have an acidophilic cytoplasm containing an extensive smooth endoplasmic reticulum. Like other cells of the adrenal cortex, the cells of the zona glomerulosa also have round, centrally oriented nuclei. The cytoplasm of these cells has numerous lipid droplets. However, these lipid droplets are too small to be viewed under the light microscope. The glomerulosa cells produce a variety of hormones collectively called the Mineralcorticoids. Principle among these products is Aldosterone which assists in the regulation of urine production.

b) Zona Fasciculata - is the middle and thickest layer of the adrenal cortex. The zona fasciculata consists of long, radially arranged columns or cords of epithelial cells called Spongiocytes. The cords of spongiocytes are generally two cells wide and are separated by fenestrated capillaries. The spongiocytes will often stain palely due to their high content of lipid droplets. The spongiocytes produce a group of hormones collectively called the Glucocorticoids. The glucocorticoids include Cortisone, Corticosterone, and Hydrocortisone which effect the inflammation response.

c) Zona reticularis - is the innermost cortical zone and is immediately adjacent to the medulla. The zona reticularis consists of anastomizing cords of epithelial cells called Reticular cells. The reticular cells produce small amounts of hormones known collectively as the Gonadocorticoids. The epithelial cells of the adrenal cortex parenchyma is supported by reticular fibers.

17.5.3. The Adrenal Medulla

The adrenal medulla is the inner portion of the adrenal gland. The boundary between the adrenal cortex and the adrenal medulla is fairly distinct (although it is less so in humans than in "lower" mammals). The products of the adrenal medulla are two types of Catecholamines. Catecholamines function as a part of the sympathetic division of the ANS. They are a prime example of the integrated control of the body conducted by both the nervous and the endocrine systems. The catecholamines act so much like the neurotransmitters of the sympathetic division that they have been termed "sympathomimetic hormones". The two catecholamines are: [a] Epinephrine - which is identical in structure and function to the neurotransmitter epinephrine produced by the sympathetic division of the ANS. [b] Norepinephrine - which is identical in structure and function to the neurotransmitter norepinephrine produced by the sympathetic division of the ANS. The parenchymal cells of the adrenal medulla are called Chromaffin cells. Chromaffin cells will occur in clumps, groups, or even short cords. The chromaffin cells are surrounded by a rich vascular plexus, as is the case for the other endocrine organs, consisting of fenestrated capillaries. They will have abundant granules in the cytoplasm. The granules are visible under electron microscopy. The granules contain the catecholamines. Due to the staining characteristics of the granules and the products they hold there are two classes of chromaffin cells recognized. Chromaffin cells are very similar to postganglionic neurons of the ANS. They are of neural crest origin. They are innervated by preganglionic fibers (sympathetic). The preganglionic neurons trigger the release of catecholamines by the chromaffin cells.

17.6. The Pineal Gland/Epiphysis Cerebri

17.6.1. General Comments

The pineal gland is a portion of the epithalamus of the diencephalon. It develops as an outgrowth of the roof of the diencephalon and remains attached by a short, cone-shaped stalk. The pineal gland developed from a parietal eye found in ancestral vertebrates. This is reflected in the fact that the pineal gland is stimulated by light to release its products. Its secretory activity is determined by photoperiod information relayed to it by nerve tracts from the eye. It is believed to establish the circadian rhythm.

17.6.2. Hormones of the Pineal Gland

The pineal gland produces a number of hormones: (i) Melatonin which stimulates melanocyte activity in lower vertebrates but may regulate body rhythms in humans. (ii) Serotonin which is important for maintaining normal brain physiology. (iii) Adrenoglomerulotropin which, if it exists, may stimulate the adrenal cortex to produce aldosterone.

17.6.3. Histology of the Pineal Gland

The pineal gland possesses a capsule which develops from the pia mater. The capsule will extend septa into the pineal gland dividing it into incomplete lobes. There are two cell populations within the parenchyma of the pineal gland:

a) Pinealocytes

These are numerous cell type making up ~95% of the cellular population in the parenchyma. Pinealocytes are elongated, branching cells whose branches terminate on adjacent fenestrated capillaries. Pinealocytes are arranged into irregular cords and follicles. They're derived from neuroepithelial cells in the roof of the diencephalon.

Pinealocytes have large nuclei that display varying degrees of folding to their nuclear membrane. Pinealocytes are the endocrine cells of the pineal gland.

b) Interstitial cells

These are far less numerous making up only about 5% of the population. The pinealocytes are located within a framework of interstitial cells. Interstitial cells are similar to, and evolved from, neuroglia. They are often referred to as neuroglia. They can be distinguished from the pinealocytes by their more elongated nuclei. One diagnostic feature of the pineal gland is Corpora Arenacea ("brain sand"). Corpora arenacea is deposits of calcium located in the connective tissue septa. This calcification begins at about puberty. It's function, cause, and meaning is unclear.